



# CLINICAL VARIANT INTERPRETATION LAB

Joe Farris, Ph.D.

Introduction to Computational Genomics

June 23<sup>rd</sup>, 2026

# Case #1

## Patient phenotype:

- Abnormality of male external genitalia, high palate, retrognathia, low-set ears, patent ductus arteriosus, hypoglycemia, abnormal pattern of respiration, ascending tubular aorta aneurysm, abnormality of the external nose, abnormal digit morphology, fetal choroid plexus cysts, short fetal femur length, heart murmur, abnormal atrioventricular valve physiology

## Variant identified via trio genome:

- *CCDC22*:c.1634A>G, Lys545Arg
- Inheritance: maternal (X-linked gene). Follow-up sequencing found the variant was not inherited from the mother's parents.

Criteria being considered	Strength being applied	Evidence	Points

## Case #2

### Patient phenotype:

- Male with retinitis pigmentosa

### Variant identified via singleton exome:

- *RPGR*:c.905G>A, Cys302Tyr
- Inheritance: Unknown

Criteria being considered	Strength being applied	Evidence	Points

# Case #3

**Patient phenotype:**

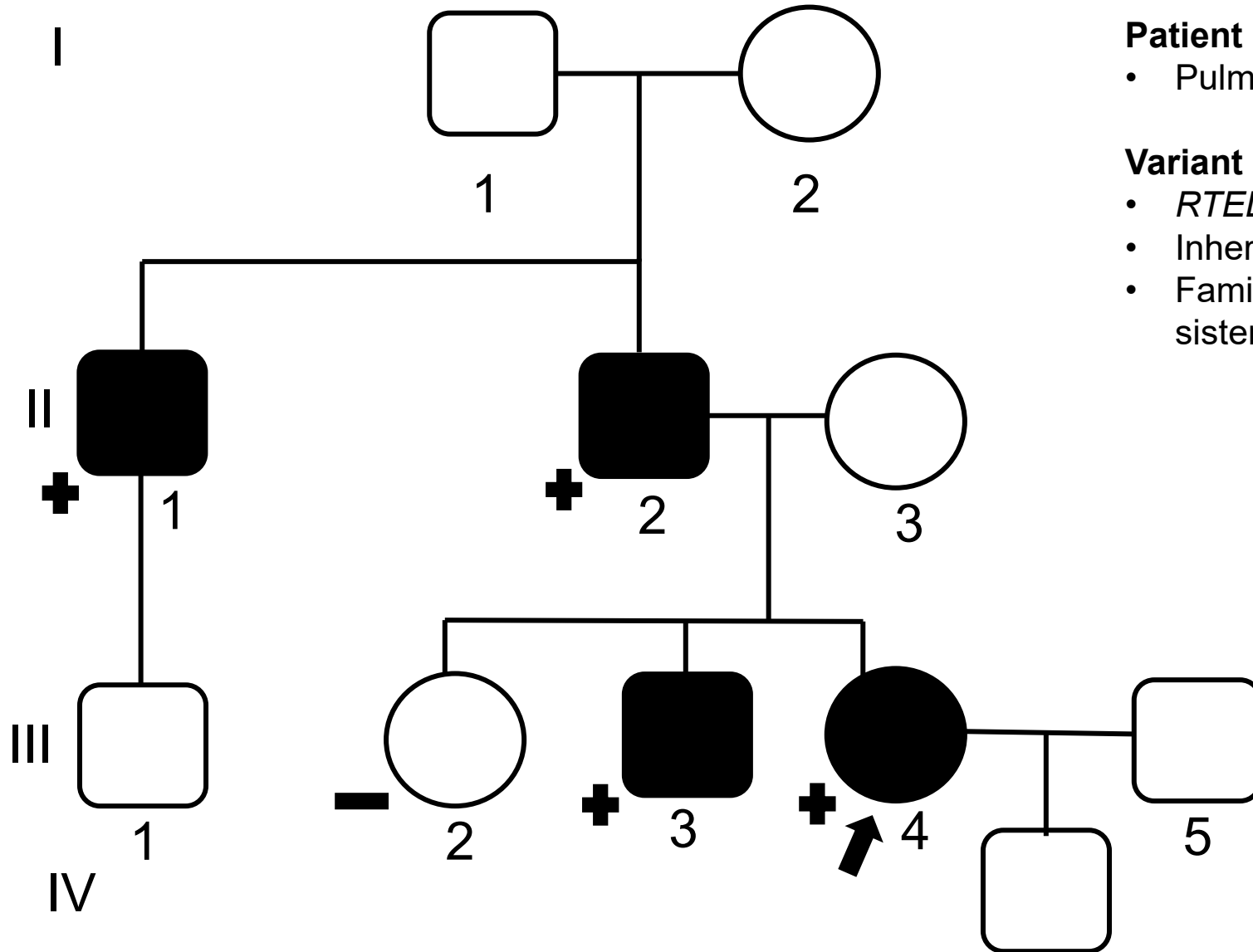
- Pulmonary fibrosis, shorted telomeres

**Variant identified via trio genome:**

- *RTEL1*:c.101A>G, Q34R
- Inheritance: Paternal
- Family history: 1 affected brother, 1 unaffected sister. Father and paternal uncle are affected.

Criteria being considered	Strength being applied	Evidence	Points

# Case #3



### Patient phenotype:

- Pulmonary fibrosis, shorted telomeres

### Variant identified via trio genome:

- *RTEL1*:c.101A>G, Q34R
- Inheritance: Paternal
- Family history: 1 affected brother, 1 unaffected sister. Father and paternal uncle are affected.

# Case #4

**Patient phenotype:**

- Developmental regression, ataxia, seizures, cerebellar atrophy, nystagmus, Dandy-Walker malformation

**Variant identified via trio genome:**

- *In trans* variants:
  - *PMPCA*:c.1204C>T, R402\*
  - *PMPCA*:c.667C>T, R223C

Criteria being considered	Strength being applied	Evidence	Points
Variant 1 R402*			
Variant 2 R223C			

# QUESTIONS & ANSWERS

